

## Minitubular Transcortical Microsurgical Approach for Gross Total Resection of Third Ventricular Colloid Cysts: Technique and Assessment

Aaron A. Cohen-Gadol

### Key words

- Brain retraction
- Colloid cyst
- Resection
- Tubular surgery

### Abbreviations and Acronyms

**MRI:** Magnetic resonance imaging



Goodman Campbell Brain and Spine, Indiana  
University Department of Neurological Surgery,  
Indianapolis, Indiana, USA

To whom correspondence should be addressed:

Aaron A. Cohen-Gadol, M.D., M.Sc.

[E-mail: [acohenmd@gmail.com](mailto:acohenmd@gmail.com)]

Citation: *World Neurosurg.* (2013) 79, 1:207.e7-207.e10.

DOI: 10.1016/j.wneu.2011.03.045

Journal homepage: [www.WORLDNEUROSURGERY.org](http://www.WORLDNEUROSURGERY.org)

Available online: [www.sciencedirect.com](http://www.sciencedirect.com)

1878-8750/\$ - see front matter © 2013 Elsevier Inc.

All rights reserved.

### INTRODUCTION

Colloid cysts may obstruct cerebrospinal fluid pathways and present with hydrocephalus. Transcortical and transcallosal-interhemispheric approaches to the third ventricle have been traditionally used for gross total resection of colloid cysts, but cortical damage and related seizures have been associated with the transcortical approach (2, 4, 17).

More recently, endoscopic techniques have made possible a less invasive approach, reaching the deep seated colloids cysts with less transection of healthy brain tissue (1, 8, 9, 18). In addition, in studies that compared endoscopy with microsurgery, endoscopy resulted in less operating time, a shorter hospital stay, and an earlier return to work for patients (11, 15). These endoscopic techniques, however, do not allow for ambidextrous microsurgical techniques and routine gross total removal of the cysts. Longatti et al. (16) reported cyst residues in 36 (62%) of the 61 patients in their study; the recurrence rate was 11.4%. Other investigators, however, have reported recurrence rates from 0 to 10% (3, 4, 1, 8, 9, 11,

■ **OBJECTIVE:** “Open” transcortical and transcallosal approaches allow gross total colloid cyst resection but require a wider surgical corridor through normal brain tissue compared with endoscopic techniques. Although the use of tubular retractor systems has been previously reported, the minimum required diameter size for the retractor tube has been approximately 16 to 22 mm. Our objective was to explore the use of smaller retractor tubes for total resection of colloid cysts.

■ **METHODS:** A minitubular retractor with a 12-mm diameter was used to access and resect colloid cysts using microsurgical techniques while preserving stereoscopic vision as an alternative to open and endoscopic surgical routes.

■ **RESULTS:** This technique was adopted in five patients with larger than 10-mm colloid cysts to allow for gross total resection of the cysts in every case without any complication.

■ **CONCLUSIONS:** Smaller retractor tubes may be used for resection of colloid cysts while minimizing brain retraction injury and potentially improving outcomes.

15). Despite these limitations, as no perfect route to resection of these lesions is available, endoscopic methods have significantly advanced removal of colloid cysts safely and effectively.


In 2005, Harris et al. (7) modified a thoracic port for use as a stereotactic transcortical conduit for endoscopically guided microsurgical lesion resection and reported minimized brain retraction and satisfactory visualization.

To facilitate the use of microsurgical techniques for complete colloid cyst removal and to simultaneously minimize the violation of healthy brain tissue when reaching these deep-seated cysts, a previously known tubular retractor system was considered as an alternative (6, 12–14). Although the smallest required tube diameter has been 16–22 mm, 10- to 12-mm minitubular retractors were evaluated. An analysis of the minimum tube diameter required for adequate stereoscopic visualization of the cyst and its surrounding structures and for manipulation of microsurgical instruments is desirable to minimize brain disruption caused by the retractor tube.

### TECHNIQUE AND METHODS

The feasibility of a transcortical minitubular retractor system to provide just enough working space to remove the cyst was evaluated. The narrowest available tube (17 mm) licensed for cranial surgery was manufactured through Vycor Medical (Bohemia, New York, USA).

The retractor tube with the minimum diameter size that would allow the application of microsurgical instruments and stereoscopic vision through the operating room microscope was explored. For this purpose, 10- and 12-mm diameter tubes (3–6 cm in length, provided by Vycor Medical and made of LEXAN HPSIR-21436 Clear Polycarbonate) were evaluated. These 10- and 12-mm diameter retractors were used to expose the foramen of Monroe through the frontal lobe in two cadavers (4 sides). The 12-mm tube exposed “enough” of the foramen and allowed reasonably comfortable maneuvering of the bayoneted microsurgical instruments with stereoscopic vision for the surgeon. The 10-mm tube was considered narrow, especially for the use of a bipolar coagulator and microscissors.

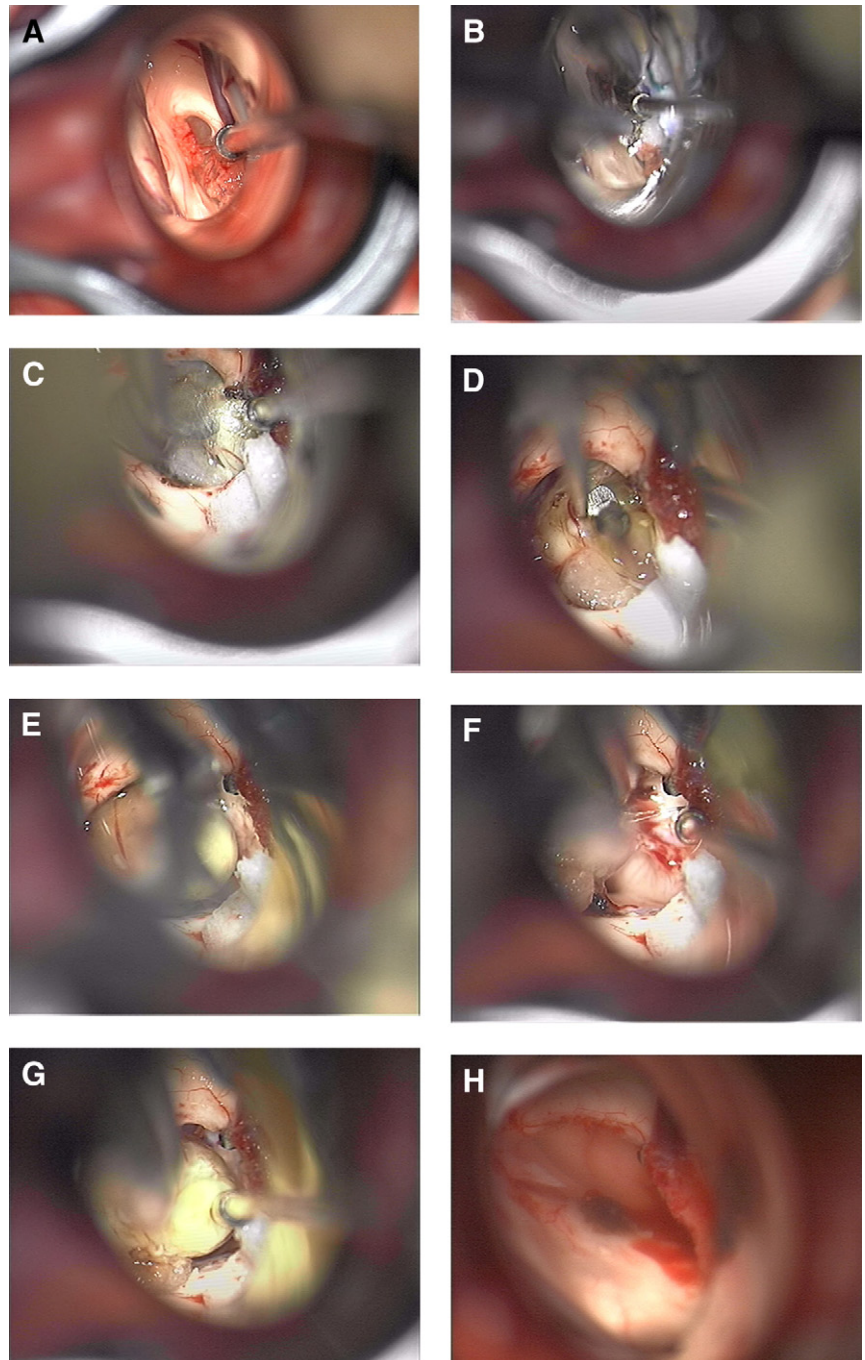


**Figure 1.** Newly designed 12-mm minitubular retractor system was used for resection of colloid cysts. It consists of an outer working channel port and an inner introducer.

Therefore, the 12-mm tube (**Figure 1**) was selected to resect the colloid cyst in the following five patients.

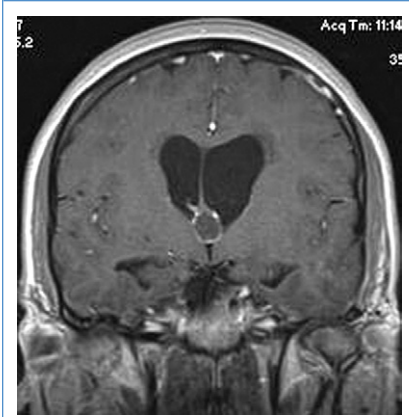After a small left frontal craniotomy just anterior to the coronal suture (the larger ventricle detected on the preoperative magnetic resonance imaging [MRI] was selected for access), frameless stereotactic neuronavigation was used to place a standard ventricular catheter into the frontal horn of the lateral ventricle aimed at the cyst or foramen of Monroe. The stylet of the ventricular catheter was then removed, and an operating room microscope was used to remove a small amount of brain tissue around and along the entire length of the catheter until the ventricle was reached and visualized through the microscope. The catheter was withdrawn and the 12-mm tubular retractor (working channel port, 5 cm in length) along with its inner introducer tube was passed through the tract. Upon return of cerebrospinal fluid, the tubular retractor system was fixed in place using a flexible arm attached to the Mayfield head holder. The inner introducer tube was removed, and after minor adjustment in the tube angle, the foramen, lesion, and surrounding relevant structures were placed in the center of the retractor's view through the microscope (**Figure 2A**).

Using standard microsurgical techniques, the cyst was first drained and then removed from the surrounding structures in a gross total fashion (**Figure 2B–H**). Bayoneted dissectors, bipolar coagulator, and microscissors were used without significant difficulty. At the end of the resection, the tube was withdrawn and the craniotomy closed in standard fashion. An external ventricular drain was not used postoperatively.



**Figure 2.** The 12-mm tubular retractor allowed adequate exposure of the foramen of Monroe, colloid cyst, and surrounding relevant structures through the stereoscopic view of an operating room microscope (**A**). After drainage of cyst contents, bipolar forceps, a small cottonoid, and suction were used to coagulated the attachments of the cyst on the ipsilateral fornix (**B**). A dissector was used to dissect the cyst wall from the surrounding structures (**C, D**). A microscissor was used to detach other attachments of the cyst to the anterior third ventricular wall (**E**). Bipolar forceps were used to detach the attachments to the contralateral structures (**F**). The cysts wall was delivered en block (**G**). Gross total resection of the cyst was possible without any significant injury to the vital surrounding structures (**H**).





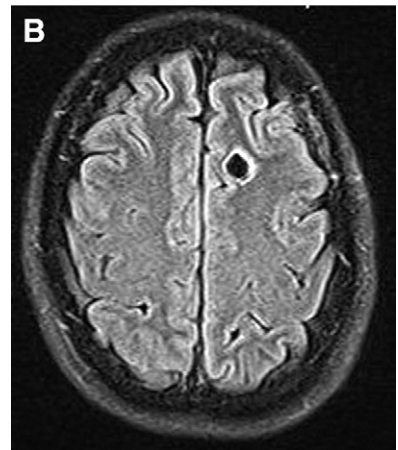
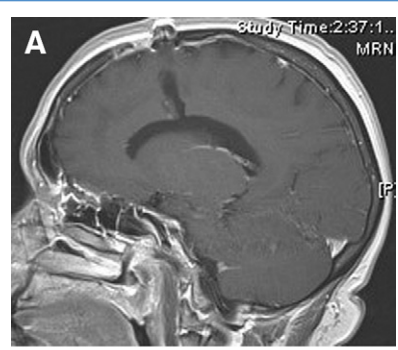
**Figure 3.** An MRI of the brain was remarkable for moderate hydrocephalus and a third ventricular colloid cyst.

## RESULTS

Five patients underwent the procedure between January 2009 and October 2010. The average age for these patients was 35 years (range 26–54 years). Their cyst size ranged from 10–22 mm (average 15 mm). Three patients harbored preoperative mild hydrocephalus. The most common presenting symptom was headaches in 80%. After the procedure, no apparent complication was encountered and all patients returned to work postoperatively. Two patients were attending school for their Master's degrees; both resumed their classes shortly after surgery (both were approached through the left ventricle with some manipulation of the left fornix). In all patients, postoperative MRI, 3 months after surgery, confirmed gross total resection of the lesion without any complicating feature. The average duration of follow-up is 10 months (range 3–18 months).

### Case Example

A 52-year-old woman presented with progressive headaches and memory difficulty. An MRI of the brain was remarkable for moderate hydrocephalus and a colloid cyst (**Figure 3**). After discussion of various surgical treatment options, resection of the cyst was deemed to have the most durable result. Transcallosal, transcortical, and endoscopic approaches were considered. The patient underwent microsurgical gross total resection of her cyst through the minitubular system, discussed previously, without any adverse effect and was discharged the



**Figure 4.** A postoperative MRI, 3 months later, confirmed gross total cyst resection (**A**) and demonstrated the relatively small extent of frontal lobe disruption caused by the retractor (**B**).

next morning. A postoperative MRI 3 months later confirmed gross total resection (**Figure 4A**) and demonstrated the relatively small extent of frontal lobe disruption caused by the retractor (**Figure 4B**).

## DISCUSSION

Transcerebral intrusion of narrow retractors and endoscopes minimizes the extent of injury to the healthy brain. The diameter of the working channel for various endoscopes used for resection of colloid cysts is around 6–8 mm. The 12-mm diameter of the minitubular retractor may compare favorably to that of an endoscope, although the endoscope, with a diameter that is about 4 mm smaller than the minitubular retractor, is likely to cause less brain disruption and provide a more panoramic view of the region. However, the minitubular retractor allows the use of an operating room micro-

scope and microsurgical techniques. In addition, the surrounding brain tissue can be seen and inspected for underlying hemorrhage through the transparent wall of this tubular system. The elliptical shape of the tube provides additional space in both directions. The inner introducer allows a smooth entry and gradual expansion of the retractor's path through the brain.

Colloid cysts and similar small size intraventricular lesions are ideal candidates to be exposed and resected through this minitubular system using the frameless stereotactic neuronavigational systems. This is especially true for the patients who do not harbor significant hydrocephalus and therefore may not be great candidates for endoscopic methods. The small surgical view provided by the 12-mm minitubular system precludes its use for resection of larger intraventricular lesions. Colloid cysts frequently adhere to the surrounding diencephalic veins. Dissection of the cyst away from these often nonexpansible, thin-walled vessels requires careful and gentle use of sharp ambidextrous microsurgical techniques, which is afforded through a microscope.

The risk of seizures and cognitive decline due to cortical injury has been a disadvantage associated with the traditional transcortical approach (19). Use of endoscopic techniques has minimized cortical injury. The risk of postoperative seizures due to the use of minitubular system is difficult to measure. There is a need for objective evaluation of patients' outcomes undergoing different techniques. Expansion of endoscopic methods will increase their role in the removal of intraventricular lesions in the future. The present study cannot evaluate the risk of cyst recurrence as it does not provide a long-term follow-up evaluation after surgery.

Patrick Kelly (12–14) popularized the use of transcerebral tubular retractor systems, which distribute pressure equally and minimize brain injury. Sharp edges of traditional retractor blades stretch and occlude perfusion to the surrounding brain parenchyma with resultant injury (20). Recently, tubular retractor systems for spinal surgery (METRx; Medtronic; Minneapolis, Minnesota, USA) have been used to approach deep brain lesions (6). However, the narrowest diameter tube that would allow the use of microsurgical techniques and a stereo-

scopic view was not explored. Other drawbacks were noted with this system. Advancing different diameter METRx retractors in a series fashion through the brain is awkward and associated with a risk of pial injury. The METRx tubes typically are offered in diameters 16–26 mm. The current Vycor retractor system avoids some of these drawbacks. Endoscopes may be used through the minitubular retractor systems to expand the field of vision (5, 10). In addition, the technique mentioned previously is a potentially superior alternative to conventional approaches for surgeons not trained in endoscopic capabilities.

## CONCLUSION

Narrow diameter tubular retractor systems may be used for resection of small intraventricular lesions such as colloid cysts as an alternative to endoscopic methods.

## REFERENCES

1. Abdou MS, Cohen AR: Endoscopic treatment of colloid cysts of the third ventricle. Technical note and review of the literature. *J Neurosurg* 89:1062-1068, 1998.
2. Abernathy CD, Davis DH, Kelly PJ: Treatment of colloid cysts of the third ventricle by stereotaxic microsurgical laser craniotomy. *J Neurosurg* 70:525-529, 1989.
3. Badie B, Brooks N, Souweidane MM: Endoscopic and minimally invasive microsurgical approaches for treating brain tumor patients. *J Neurooncol* 69:209-219, 2004.
4. Decq P, Le Guerinel C, Brugières P, Djindjian M, Silva D, Kéravel Y, Melon E, Nguyen JP: Endoscopic management of colloid cysts. *Neurosurgery* 42:1288-1294 [discussion: 1294-1296], 1998.
5. Engh JA, Lunsford LD, Amin DV, Ochalski PG, Fernandez-Miranda J, Prevedello DM, Kassam AB: Neurosurgery. Stereotactically guided endoscopic port surgery for intraventricular tumor and colloid cyst resection. *Neurosurgery* 67(3 Suppl Operative):198-204 [discussion: 204-205], 2010.
6. Greenfield JP, Cobb WS, Tsouris AJ, Schwartz TH: Stereotactic minimally invasive tubular retractor system for deep brain lesions. *Neurosurgery* 63(4 Suppl 2):334-339 [discussion: 339-340], 2008.
7. Harris AE, Hadjipanayis CG, Lunsford LD, Lunsford AK, Kassam AB: Microsurgical removal of intraventricular lesions using endoscopic visualization and stereotactic guidance. *Neurosurgery* 56(1 Suppl):125-132 [discussion: 125-132], 2005.
8. Hellwig D, Bauer BL, Schulte M, Gatscher S, Riegel T, Bertalanffy H: Neuroendoscopic treatment for colloid cysts of the third ventricle: the experience of a decade. *Neurosurgery* 52:525-533 [discussion: 532-533], 2003.
9. Horn EM, Feiz-Erfan I, Bristol RE, Lekovic GP, Goslar PW, Smith KA, Nakaji P, Spetzler RF: Treatment options for third ventricular colloid cysts: comparison of open microsurgical versus endoscopic resection. *Neurosurgery* 60:613-618 [discussion: 618-620], 2007.
10. Jho HD, Alfieri A: Endoscopic removal of third ventricular tumors: a technical note. *Minim Invasive Neurosurg* 45:114-119, 2002.
11. Kehler U, Brunori A, Gliemroth J, Nowak G, Delitala A, Chiappetta F, Arnold H: Twenty colloid cysts—comparison of endoscopic and microsurgical management. *Minim Invasive Neurosurg* 44:121-127, 2001.
12. Kelly PJ: Future perspectives in stereotactic neurosurgery: stereotactic microsurgical removal of deep brain tumors. *J Neurosurg Sci* 33:149-154, 1989.
13. Kelly PJ, Goerss SJ, Kall BA: The stereotaxic retractor in computer-assisted stereotaxic microsurgery. Technical note. *J Neurosurg* 69:301-306, 1988.
14. Kelly PJ, Kall BA, Goerss SJ: Computer-interactive stereotactic resection of deep-seated and centrally located intraaxial brain lesions. *Appl Neurophysiol* 50:107-113, 1987.
15. Lewis AI, Crone KR, Taha J, van Loveren HR, Yeh HS, Tew JM Jr: Surgical resection of third ventricle colloid cysts. Preliminary results comparing transcallosal microsurgery with endoscopy. *J Neurosurg* 81:174-178, 1994.
16. Longatti P, Godano U, Gangemi M, Delitala A, Morace E, Genitori L, Alafaci C, Benvenuti L, Brunori A, Cereda C, Cipri S, Fiorindi A, Giordano F, Mascari C, Oppido PA, Perin A, Tripodi M; Italian Neuroendoscopy Group: Cooperative study by the Italian neuroendoscopy group on the treatment of 61 colloid cysts. *Childs Nerv Syst* 22:1263-1267, 2006.
17. Morita A, Kelly PJ: Resection of intraventricular tumors via a computer-assisted volumetric stereotactic approach. *Neurosurgery* 32:920-926 [discussion: 926-927], 1993.
18. Rodziewicz GS, Smith MV, Hodge CJ Jr: Endoscopic colloid cyst surgery. *Neurosurgery* 46:655-660 [discussion: 660-662], 2000.
19. Solaroglu I, Beskonakli E, Kaptanoglu E, Okutan O, Ak F, Taskin Y: Transcortical-transventricular approach in colloid cysts of the third ventricle: surgical experience with 26 cases. *Neurosurg Rev* 27:89-92, 2004.
20. Zhong J, Dujovny M, Perlin AR, Perez-Arjona E, Park HK, Diaz FG: Brain retraction injury. *Neurol Res* 25:831-838, 2003.

*Conflict of interest statement: The author declares that the article content was composed in the absence of any commercial or financial relationships that could be construed as a potential conflict of interest.*

*Received November 22, 2010; accepted March 30, 2011*

*Citation: World Neurosurg. (2013) 79, 1:207.e7-207.e10.*

*DOI: 10.1016/j.wneu.2011.03.045*

*Journal homepage: [www.WORLDNEUROSURGERY.org](http://www.WORLDNEUROSURGERY.org)*

*Available online: [www.sciencedirect.com](http://www.sciencedirect.com)*

*1878-8750/\$ - see front matter © 2013 Elsevier Inc.*

*All rights reserved.*